

# Inoperable Stage I/II Melanoma: Efficacy of Anti-PD1 Immunotherapy

Chirine Rezzag<sup>1</sup>, Anne Durlach<sup>2</sup>, Florent Grange<sup>1</sup>

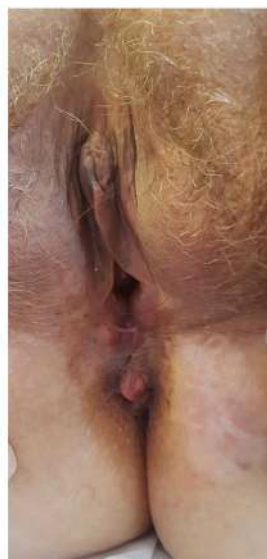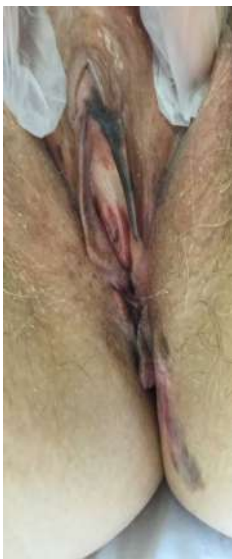<sup>1</sup>Dermatologie, <sup>2</sup>Anatomopathologie, CHU de Reims, Reims, France

## Introduction

Anti-PD1 antibodies are indicated for inoperable stage III or IV melanomas. In rare cases, stage I or II melanomas are not amenable to surgery due to their location (often mucosal or acral) and/or the extent of the lesion (e.g., face), where surgery is either unfeasible or unacceptable due to its mutilating or debilitating nature. We report on 11 patients treated in this situation with anti-PD1 therapy.

## Materials and Methods

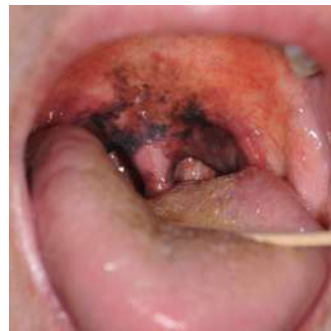All patients treated with anti-PD1 between January 2018 and April 2020 for a stage I or II melanoma (AJCC8) for which surgery was excluded by the multidisciplinary team were included. The primary endpoint was the best response rate, including complete and partial responses. Secondary endpoints included overall survival, progression-free survival, toxicity, and response calculated from the first treatment date.



**Patient No. 9: Extensive Vulvar Melanoma**

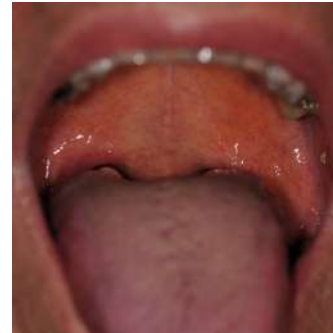
Before treatment introduction

After 1 year of treatment:  
Complete remission,  
histologically proven



**Patient No. 7: Hard Palate Melanoma**

Before treatment introduction



After 2 years of treatment:  
Complete remission,  
histologically proven

## Results

11 patients with an average age of 77 years (range: 49-90) were included.

5 received nivolumab, 5 pembrolizumab, and 1 cemiplimab for an inoperable cutaneous squamous cell carcinoma of a limb, which was the primary indication.

The melanoma was cutaneous in 7 cases and mucosal in 4 cases. The lesion surface area ranged from 8 to 44 cm<sup>2</sup>.

Three tumors were in situ melanomas, and 8 were invasive melanomas. For the three in situ cases, surgery was rejected due to the size of the lesion, proximity to the eye, or age.

7 of the 8 invasive melanomas had a Breslow thickness of 0.35 to 12 mm, measured from partial biopsies of the thickest part of the tumor (7 cases) or MRI (1 case). All melanomas were BRAF wild-type and expressed low levels of PD-L1 in immunohistochemistry (< 1%: 9 cases; < 5%: 2 cases).

The median duration of treatment at the data cutoff was 12 months (range: 2-19), and the median follow-up duration was 15 months (range: 3.9-45.7).

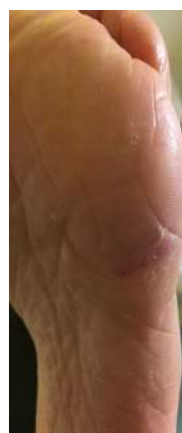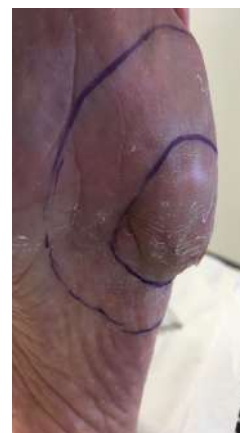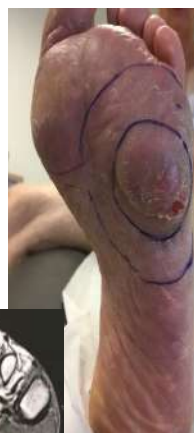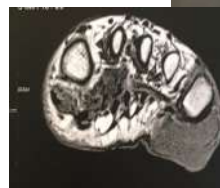A complete response was achieved in 7 cases, including 3 of the 4 mucosal melanomas; 1 partial response was observed in 3 cases, and 1 case showed no response.

The overall best response rate was 91%, with 64% achieving a complete response and 27% a partial response. No patient experienced grade  $\geq 3$  toxicity or required prolonged treatment.

## Discussion

Anti-PD1 therapies are a promising alternative for inoperable stage I-II melanomas, including mucosal melanomas, which are typically less responsive to these treatments in metastatic stages compared to cutaneous melanomas.

The complete response rate seems higher than in more advanced stages, regardless of PD-L1 expression. A prospective study with strict inoperability criteria could be proposed.



**Patient No. 5: Left Plantar Melanoma**

Before treatment introduction:  
12 mm thickness on MRI

After 1 year of treatment